

CLINICAL SHORT-TERM OUTCOMES OF LASER HEMORRHOIDOPLASTY: A MULTICENTER STUDY

Chong HY^{1,2}, Roslani AC^{1,2}, Rajandram R¹, Kumar S^{1,2}, Malik AA^{1,2}, Law CW^{1,2}, Chan SH³, Rajasingam V⁴, and Kasipillai J⁴.

¹Department of Surgery, Faculty of Medicine, Universiti Malaya, 50603 Kuala Lumpur, Malaysia

²Universiti Malaya Medical Centre, 59100 Kuala Lumpur, Malaysia

³Pantai Hospital Ampang, 55100 Kuala Lumpur, Malaysia

⁴Assunta Hospital, 46990 Petaling Jaya, Selangor, Malaysia

Correspondence:

April Camilla Roslani,

Department of Surgery,

Faculty of Medicine,

Universiti Malaya

50603 Kuala Lumpur, Malaysia

Universiti Malaya Medical Centre

59100 Kuala Lumpur,

Malaysia

Phone number: +60379492441

Fax number: +60379586360

Email: april@ummc.edu.my

Abstract

Background: Laser hemorrhoidoplasty (LHP) is a treatment for symptomatic internal hemorrhoids. Nevertheless, there are disparities in the technique employed, including combining it with pedicle ligation. We aimed to investigate if short-term clinical outcomes were different between patients undergoing LHP with and without pedicle.

Methods: Patients who underwent LHP from a prospective registry of 3 centers were identified. Demographics, severity, symptoms, operative technique, post-operative pain, complications, and recurrence were investigated. Sub-investigation of patients with simultaneous pedicle ligation, and without, was performed. Statistical analysis was done using the χ^2 test. P values <0.05 were noted as statistically significant.

Results: One hundred and two patients (59.8% male) of a mean age of 45 years were assessed. Most (62.7%) had 3rd degree hemorrhoids. Median operative time was 24 minutes (10-60 minutes) minutes. Post-operative length of stay was 26 hours (2-168 hours) hours. Median pain score 24 hours post-operatively was 0/10. The general complication percentage was 26.5%, but majority complications were self-limiting. The most common complication was post-operative swelling (16 patients; 15.7%). Post-operative bleeding was seen in 9 patients (8.8%) at a median of 7 (1-14) days, 3 of whom needed operation and readmission. Then 4 patients (3.9%) had moderate-to-severe pain (pain score of more than 5/10), 2 patients (2.0%) developed ulceration and 3 patients (2.9%) had recurrence, were treated conservatively. Patients with pedicle ligation had a higher complication (33.3% vs. 14.8%; p=0.08), mainly bleeding and swelling but not statistically significant.

Conclusions: LHP demonstrates good short-term outcomes with minimal complication and recurrence incidences. Supplementary ligation of pedicles does not provide additional benefits, and in fact, may worsen outcomes.

Keywords: Hemorrhoids, Ligation, Outcomes, Pedicle, Short-term

Introduction

Symptomatic internal hemorrhoids worldwide are likely to be under-reported, owing to poor health seeking behaviors among these sufferers. Even in developed countries like United States, the actual prevalence is thought to be higher than reported figures (1-4). Clinically, the term 'internal hemorrhoids' is used to describe atypical enlargement of anal cushions, but more accurately, this classification should be restricted to symptomatic hemorrhoidal disease:

i.e., anal cushions are named "hemorrhoids" when hemorrhage, prolapse or other symptoms are present (5).

One of the newer options for treatment of symptomatic internal hemorrhoids is laser hemorrhoidoplasty (LHP). LHP was first described by Karahaliloğlu in 2010 (6). It uses thermal energy created by a diode laser with a wavelength of 980 nm to treat symptomatic internal hemorrhoids. The controlled emission of laser energy, which is applied to the sub-mucosa, causes the hemorrhoidal tissue to shrink (7).

Subsequent fibrosis ensures that the mucosa adheres to the underlying tissue, thus preventing occurrence or recurrence of prolapse (8). Early series have conveyed promising outcomes, with negligible post-operative pain, short operating time, few serious post-operative complications and low recurrence proportion (6, 9-11). Nevertheless, there are differences in the technique applied (12, 13). Some surgeons choose to combine LHP with hemorrhoidal pedicle ligation, which, in theory, could further reduce post-operative bleeding and recurrence. The objective of this study investigated if short-term clinical outcomes were different between patients undergoing LHP with and without pedicle.

Materials and Methods

Study Design and Participants

Patients from three institutions, who underwent LHP between December 2011 and October 2013, were identified from an observational prospectively maintained registry. This study was approved by the respective institution’s medical ethics committee and/or Hospital Director, where applicable. Written informed consent was obtained from patients for inclusion in this study. Data analyzed included that on demographics, severity, symptoms, operative technique, post-operative pain using Visual Analogue Score (VAS), complication and recurrence (Figure 1).

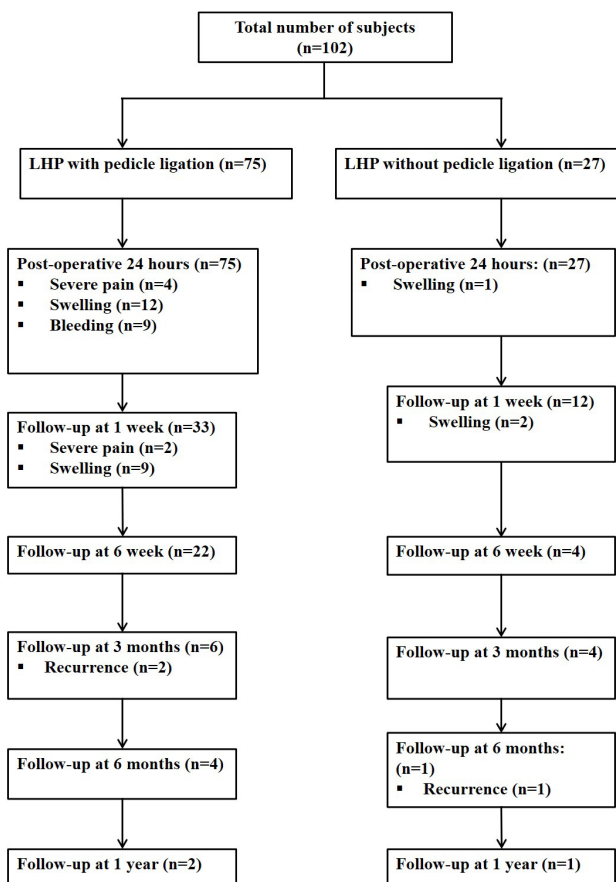


Figure 1: Consort diagram

Surgical technique

The Ceralas D 50 Evolve Laser (Biolitec AG, Jena, Germany), a 980 nm diode laser, was used for this treatment. The procedure was performed either under general or spinal anesthesia. Patients were placed in either Lloyd-Davies or prone jack-knife position. An anoscope was inserted into the anal canal and the hemorrhoids were identified (Figure 2). A small incision was made at the dentate line, caudal to the hemorrhoids, using a scalpel (Figure 3). Through the incision, the 1.8 mm radial fiber was guided into the sub-mucosal tissue (Figure 4). Next, pulsed energy of 15W was delivered for three seconds. The fiber was then pulled back at intervals of 5 mm, and the process was repeated. After each delivery, the hemorrhoidal node was chilled with compression, using ice water-soaked gauze packs. The hemorrhoidal pedicles were either suture-ligated or not ligated according to the preference of the operating surgeon. The procedure was then repeated on other hemorrhoidal nodes. The incisions were left open (Figure 5).

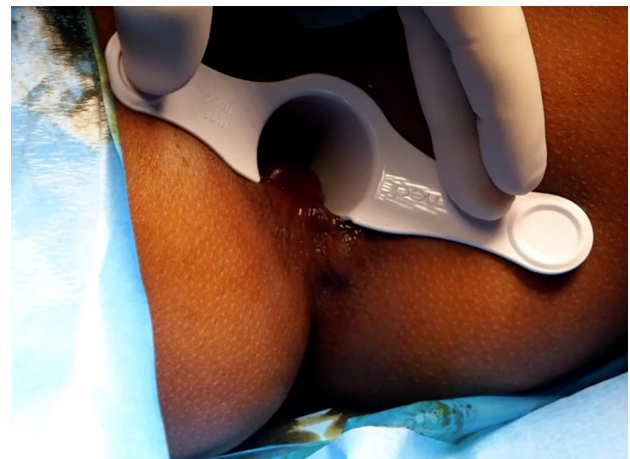

Figure 2: Identification of the hemorrhoids

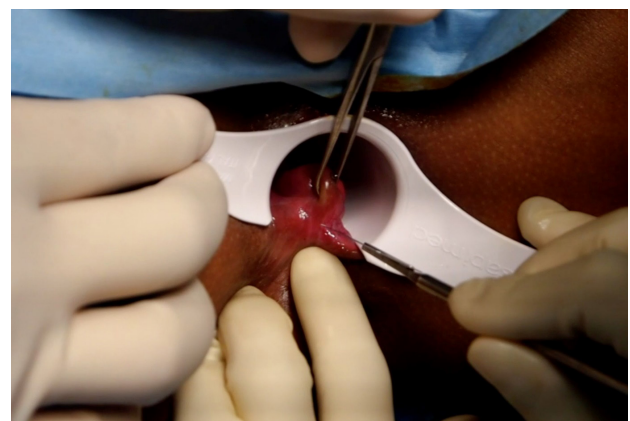

Figure 3: Incising the dentate line

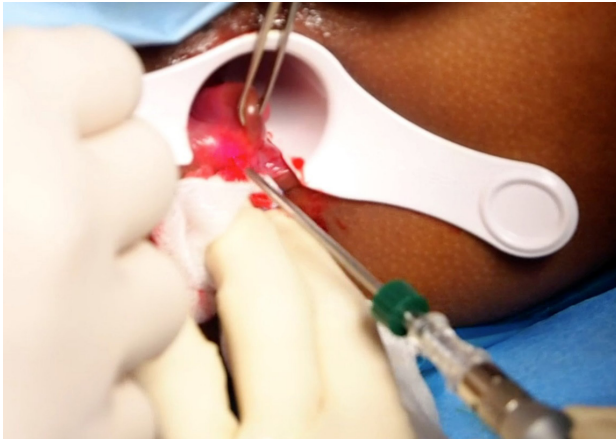


Figure 4: Introduction of the laser fiber

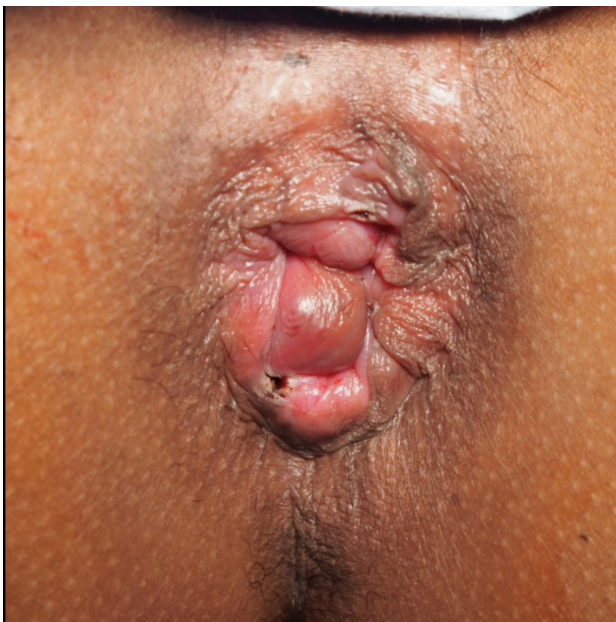

Figure 5: Post-procedural appearance

Data acquisition and analysis

Patients were followed up at 1 week, 6 weeks, 3 months, 6 months and 1 year post-operatively. During follow-up, pain scores, swelling, bleeding, recurrence, and other new symptoms were assessed.

Data up to a year post-operatively was included. Sub-analysis of patients with concurrent pedicle ligation, and without, was conducted. Statistical analysis was performed using the χ^2 test; a P value of <0.05 was considered statistically significant.

Results

Demographics distributions

A total of 102 patients were included in the study. There were 61 males (59.8%) and 41 females of a mean age of

45 (range, 21 to 76) years. The majority (62.7%) had 3rd degree hemorrhoids (Table 1).

Table 1: Patient demographics

Demographics	n	%
Gender		
Male	61	59.8
Female	41	40.2
Grade of hemorrhoids		
First degree	6	5.9
Second degree	14	13.7
Third degree	64	62.8
Fourth degree	18	17.6
Previous intervention		
Rubber banding ligation	7	6.9
Open hemorrhoidectomy	2	2.0
Pre-operative symptoms		
Pain	23	22.5
Bleeding	94	92.2
Prolapse	80	78.4
Pruritus	4	3.9
Discharge	4	3.9

Short-term clinical outcomes

Post-operative bleeding was seen in 9 patients (8.8%) at a median of 9 (1 to 14) days, 3 of whom required surgery and readmission (Table 1). Median operative time was 24 (range, 10 to 60) minutes and post-operative length of stay was 26 (range, 2 to 168) hours. The mean follow-up period was 5.6 (range, 0 to 52; standard deviation=9.48) weeks (Table 2).

Table 2: Operative data

Median operative time, minutes (range)	20 (10–60)
Median postoperative length of hospital stay, hours (range)	26 (2-168)
Suture ligation, n (%)	
Yes	75 (73.5)
No	27 (26.5)
Mean follow-up, weeks (range)	5.6 (0-52)
Complication rate (%)	28.4%
Recurrence rate (%)	2.9%

The overall complication rate was 28.4%, but most complications were self-limiting. The most common complication was post-operative swelling (16 patients; 15.7%). Swelling developed within 24 hours in 13 patients (81.2%) and 3 patients developed delayed swelling one week post-operatively. Nevertheless, the swelling resolved spontaneously in 9 patients who came for subsequent follow-up six weeks post-operatively (Table 2). The median pain score 24 hours post-operatively was 0/10 (range 0 to 8/10). Here 4 patients (3.9%) had moderate-to-severe pain (pain score of more than 5/10), which persisted for up to one week after surgery in 2 patients. The median pain score

in subsequent follow-up one week and six weeks post-operatively were 0/10 (range, 0 to 7/10 in one week and 0 to 1/10 in 6 weeks). Ulceration was found in 2 patients (2.0%). The overall recurrence rate was 2.9% (3 patients). Two patients developed recurrence at three months and 1 patient had recurrence at six months. All recurrences were treated conservatively (Table 3).

Table 3: Short-term outcomes

Symptoms	n (%)
Post-operative swelling	
At 24 hours	13 (12.8)
At one week	3 (2.9)
Post-operative bleeding	
Conservative treatment	6 (5.9)
Needs hemostatic suture	3 (2.9)
Severe pain (Pain score > 5/10)	4 (3.9)
Ulceration	2 (2.0)

Hemorrhoidal pedicle ligation versus non-ligation

A total of 75 patients (73.5%) had the procedure done with pedicle ligation. Patients with pedicle ligation had a trend to higher incidence of complications than without pedicle ligation (33.3% vs. 14.8%; $p=0.08$), predominantly bleeding and severe pain, although this was not statistically significant. It is important to note that the ligation arm had more severe disease and this was statistically significant ($P<0.05$). There was no difference in recurrence rates (Table 4).

Table 4: Comparison of outcomes between pedicle ligation and without pedicle ligation

	With pedicle ligation, n (%)	Without pedicle ligation n, (%)	P value ^a
Severity			0.779
Early (first and second degree)	14 (18.7)	6 (22.2)	
Late (third and fourth degree)	61 (81.3)	21 (77.8)	
Severity			0.046
First degree	4 (5.3)	2 (7.4)	
Second degree	10 (13.3)	4 (14.8)	
Third degree	43 (57.3)	21 (77.8)	
Fourth degree	18 (24.0)	0	
Overall complications	25 (33.3)	4 (14.8)	0.084
Post-operative swelling	13 (17.3)	3 (11.1)	0.550
Post-operative bleeding	9 (12.0)	0	0.108
Severe pain	4 (5.3)	0	0.571
Ulceration	1 (1.3)	1 (3.7)	0.461
Recurrence	2 (2.7)	1 (3.7)	1.000

^aChi-square test; The significant level was set at <0.05

Discussion

Treatment of hemorrhoids using laser energy was first described in the 1980s (14). Many authors have advocated the usage of laser energy to perform hemorrhoidectomy for both external and internal hemorrhoids, as well as external hemorrhoids alone. Earlier studies using CO₂ laser or Nd:YAG laser showed promising positive results (14-18). However, a randomized trial comparing Nd:YAG laser to cold scalpel did not distinguish any difference. Moreover, the trial reported higher costs and poorer wound healing with the usage of this laser (19, 20). These earlier studies were conducted using laser probes which radiated energy linearly, and had minimal circumferential effects. Therefore, they were only suitable for use as resectors, as was their utilization in hemorrhoidectomy (21, 22). On the other hand, newer laser probes produce radial energy with limited penetration, which maximizes local circumferential heating without damaging non-targeted surrounding structures, and are thus ideally suited to non-resectional treatment of internal hemorrhoids (22-26).

The LHP technique is relatively new, and therefore, there is limited data on its efficacy and safety. Our data corroborate the little available published data that this technique is safe, with low short-term complication and recurrence rates (6). In Karahaliloglu's series, post-operative bleeding needing ligation was seen in 2.7%, post-operative swelling in 13.0% and necrosis was noted in 0.3% of patients. Other reported complications include abscess formation (0.6%), fistula formation (0.6%), perianal thrombosis (1.5%) and fibroma formation (7.8%), none of which was seen in our series. However, we reported a lower recurrence rate (2.9% vs. 5.8%). This may be due to a shorter follow-up period in our study. Jahanshahi et al. (2012) (10), on the other hand, reported a complication rate (3.51%) and zero recurrence in their series of 341 patients with follow-up of up to one year.

The addition of prophylactic ligation of hemorrhoidal pedicles to the procedure does not appear to offer added benefits and may even worsen outcomes. Our series showed that patients with added pedicle ligation had a definite trend to higher incidence of post-operative bleeding, swelling and severe pain, although this did not attain statistical significance. One possible explanation is that suture-ligation is not only traumatic, but induces a relative ischemia, resulting in more edema, ulceration, bleeding and severe pain, the latter particularly if it is performed close to the dentate line (27).

Strengths and limitations

The results of this technique are also comparable with other established techniques of treatment of internal hemorrhoids, namely the procedure for prolapse and hemorrhoids (PPH), which have low complication and recurrence rates (28-30). The added advantage of LHP compared to PPH is there is less likelihood of stricture formation post-operatively.

The lack of a standardized follow-up protocol between centers, resulting in a short median follow-up period, are the main limiting factors in this study. Many patients were discharged from clinical follow-up within six weeks after the procedure and asked to return only if new symptoms arose. Nevertheless, we believe this series to be useful for hypothesis-generation in the design of future randomized-controlled trials.

While the LHP procedure is simple to perform, and appears safe for patients, there are considerable obstacles to its widespread implementation. Although the laser energy used has limited penetration, there is still the potential for harm to the surgeons and medical personnel. Precautions with respect to attire, operating room etiquette and infrastructure must be adopted. Furthermore, the direct costs of this procedure are much higher than other indicated procedures, particularly in developing economies.

Conclusion

Based on these study findings LHP demonstrates good short-term outcomes with minimal complication and recurrence incidences. Supplementary ligation of pedicles does not provide additional benefits and in fact, may worsen outcomes. Randomized controlled trials and cost-analysis are essential to determine the long-term of LHP role as treatment for internal hemorrhoids.

Competing interest

The authors declare that they have no competing interests.

References

- Gallo G, Martellucci J, Sturiale A, Clerico G, Milito G, Marino F, *et al.* Consensus statement of the Italian society of colorectal surgery (SICCR): management and treatment of hemorrhoidal disease. *Tech Coloproctol.* 2020;24(2):145-64.
- Hall JF. Modern management of hemorrhoidal disease. *Gastroenterol Clin North Am.* 2013;42(4):759-72.
- Riss S, Weiser FA, Schwameis K, Riss T, Mittlböck M, Steiner G, *et al.* The prevalence of hemorrhoids in adults. *Int J Colorectal Dis.* 2012;27(2):215-20.
- Lohsiriwat V. Hemorrhoids: from basic pathophysiology to clinical management. *World J Gastroenterol.* 2012;18(17):2009-17.
- Margetis N. Pathophysiology of internal hemorrhoids. *Ann Gastroenterol.* 2019;32(3):264-72.
- Karahaliloğlu AF. Die Laserhämorrhoidoplastie (LHP). *Coloproctol.* 2010;32:116-23.
- Giamundo P, Braini A, Calabro G, Crea N, De Nardi P, Fabiano F, *et al.* Doppler-guided hemorrhoidal dearterialization with laser (HeLP): a prospective analysis of data from a multicenter trial. *Tech Coloproctol.* 2018;22(8):635-43.
- Wynn TA, Ramalingam TR. Mechanisms of fibrosis: therapeutic translation for fibrotic disease. *Nat Med.* 2012;18(7):1028-40.
- Giamundo P, Salfi R, Geraci M, Tibaldi L, Murru L, Valente M. The hemorrhoid laser procedure technique vs rubber band ligation: a randomized trial comparing 2 mini-invasive treatments for second- and third-degree hemorrhoids. *Dis Colon Rectum.* 2011;54:693-8.
- Jahanshahi A, Mashhadizadeh E, Sarmast MH. Diode laser for treatment of symptomatic hemorrhoid: a short term clinical result of a mini invasive treatment, and one year follow up. *Pol Przegl Chir.* 2012;84(7):329-32.
- Plapler H, Hage R, Duarte J, Lopes N, Masson I, Cazarini C, *et al.* A new method for hemorrhoid surgery: intrahemorrhoidal diode laser, does it work? *Photomed Laser Surg.* 2009;27(5):819-23.
- Brusciano L, Gambardella C, Terracciano G, Gualtieri G, Schiano di Visconte M, Tolone S, *et al.* Postoperative discomfort and pain in the management of hemorrhoidal disease: laser hemorrhoidoplasty, a minimal invasive treatment of symptomatic hemorrhoids. *Updates Surg.* 2020;72(3):851-7.
- Danys D, Pacevicius J, Makunaite G, Palubeckas R, Mainelis A, Markevicius N, *et al.* Tissue coagulation in laser hemorrhoidoplasty - an experimental study. *Open Med (Wars).* 2020;15:185-9.
- Wang JY, Chang-Chien CR, Chen JS, Lai CR, Tang RP. The role of lasers in hemorrhoidectomy. *Dis Colon Rectum.* 1991;34(1):78-82.
- Hodgson WJB, Morgan J. Ambulatory hemorrhoidectomy with CO2 laser. *Dis Colon Rectum.* 1995;38(12):1265-9.
- Iwagaki H, Higuchi Y, Fuchimoto S, Orita K. The laser treatment of hemorrhoids: —results of a study on 1816 patients. *Jpn J Surg.* 1989;19(6):658-61.
- Riedlinger J. The surgical treatment of hemorrhoids by means of the carbon dioxide laser. In: Atsumi K, ed. *Laser-Tokyo '81.* Tokyo: Intergroup Corporation. 1981;23:30-1.
- Mokhniuk YN, Baltaitis YU, Maltsev VN, Iurzhenko VP, Korolenko VB. Comparative evaluation of methods of treatment of patients with hemorrhoids. *Clin Surg.* 1983;2:1-4.
- Senagore A, Mazier WP, Luchtefeld MA, MacKeigan JM, Wengert T. Treatment of advanced hemorrhoidal disease: a prospective, randomized comparison of cold scalpel vs. contact Nd:YAG laser. *Dis Colon Rectum.* 1993;36(11):1042-9.
- Senagore AJ, Singer M, Abcarian H, Fleshman J, Cormann M, Wexner S, *et al.* A prospective, randomized, controlled multicenter trial comparing stapled hemorrhoidopexy and Ferguson hemorrhoidectomy: perioperative and one-year results. *Dis Colon Rectum.* 2004;47(11):1824-36.
- Maloku H, Gashi Z, Lazovic R, Islami H, Juniku-Shkololli A. Laser hemorrhoidoplasty procedure vs open surgical hemorrhoidectomy: a trial comparing 2 treatments for hemorrhoids of third and fourth degree. *Acta Inform Med.* 2014;22(6):365-7.

22. Longchamp G, Liot E, Meyer J, Toso C, Buchs NC, Ris F. Non-excisional laser therapies for hemorrhoidal disease: a systematic review of the literature. *Lasers Med Sci.* 2021;36(3):485-96.
23. Giamundo P, Braini A, Calabro G, Crea N, De Nardi P, Fabiano F, *et al.* Doppler-guided hemorrhoidal dearterialization with laser (HeLP): indications and clinical outcome in the long-term. Results of a multicenter trial. *Surg Endosc.* 2022;36(1):143-8.
24. Cristea C, Lewis CR. Hemorrhoidectomy. In: *StatPearls.* Treasure Island (FL): StatPearls Publishing. 2021.
25. Ng KS, Holzgang M, Young C. Still a case of “No Pain, No Gain”? An updated and critical review of the pathogenesis, diagnosis, and management options for hemorrhoids in 2020. *Ann Coloproctol.* 2020;36(3):133-47.
26. Weyand G, Theis CS, Fofana AN, Rudiger F, Gehrke T. Laserhemorrhoidoplasty with 1470 nm diode laser in the treatment of second to fourth degree hemorrhoidal disease - a cohort study with 497 patients. *Zentralbl Chir.* 2019;144(4):355-63.
27. Sun Z, Migaly J. Review of hemorrhoid disease: presentation and management. *Clin Colon Rectal Surg.* 2016;29(1):22-9.
28. Fueglistaler P, Guenin MO, Montali I, Kern B, Peterli R, von Flüe M, *et al.* Long-term results after stapled hemorrhoidopexy: high patient satisfaction despite frequent postoperative symptoms. *Dis Colon Rectum.* 2007;50(2):204-12.
29. Kahlke V, Bock JU, Peleikis HG, Jongen J. Six years after: complications and long-term results after stapled hemorrhoidopexy with different devices. *Langenbecks Arch Surg.* 2011;396(5):659.
30. Riss S, Riss P, Schuster M, Riss T. Long term results after stapled anopexy for symptomatic haemorrhoidal prolapse. *Eur Surg.* 2008;40(1):30-3.